

SAPROPHYTE IDENTIFICATION CHART

SUMMARY

Saprophytic fungi or saprophytes usually live on decaying vegetation, such as sticks, leaves and logs, and are commonly found throughout the environment. Because of their prevalence, they may be confused with parasitic pathogenic fungi or dermatophytes during culture, though their presence usually does not indicate disease. They are commonly observed in human and veterinary clinical practice and can be identified by their form and manner of spore production, along with the characteristic appearance of hyphae and mycelium.^(2,3,5,6,8-11) In addition, saprophytes tend to grow more slowly on culture media than dermatophytes, but their positive identification may be important in cases where they are suspected as being the primary pathogen.

Special conditions under which saprophytes are potentially pathogenic are due to: allergic reactions, immunocompromised patients, patients with a history of prolonged antibiotic therapy, patients with chronic medical conditions or disease such as diabetes, cystic fibrosis, cancer, tuberculosis, immunologic disorders, chromomycosis, equine respiratory disease, or in patients who have undergone transplants and are on immunosuppressive therapy.

1. Some commonly encountered saprophytes in human and veterinary clinical practice:^(1,2,4,5,7,10)

- a. *Alternaria* spp.
- b. *Aspergillus* spp.
- c. *Penicillium* spp.

***Alternaria* spp.:** *Alternaria* is commonly isolated from plants, soil, food and indoor environments. It is dematiaceous and produces a melanin-like pigment that is characteristic of its growth. *Alternaria alternata* is the most common species isolated from patient specimens. In general, *Alternaria* spp. are considered opportunistic pathogens, particularly in immunosuppressed patients, and their colonization may lead to the development of invasive disease. *Alternaria* are among the primary agents of otitis media in agricultural field workers. However, due to their ubiquitous nature, they are common laboratory contaminants and their isolation in culture requires careful evaluation.

***Aspergillus* spp.:** *Aspergillus* is a ubiquitous fungus found in nature and commonly isolated from soil, decaying vegetation such as compost heaps, air vents, and on airborne dust in indoor environments. *Aspergillus* is generally the most commonly isolated fungus involved in invasive infections and it is well-known to play a role in clinical settings for the following reasons: (1) opportunistic infection; (2) allergic states; and (3) toxicoses. Patients who are immunosuppressed are at greatest risk for infection and infections may present in a wide spectrum from localized to dissemination or aspergillosis. Aspergillosis is a lung infection caused by the fungus with the primary cause being inhalation of spores. Infection can also occur in ear canals and sinuses, but generally affects open spaces or cavities within the body, such as those in the lungs.

***Penicillium* spp.:** In general, *Penicillium* spp. are commonly considered contaminants, but on occasion may cause infection; the resulting disease is generically known as penicilliosis. *Penicillium* spp. have been isolated from patients with keratitis, pneumonia, urinary tract infections, endophthalmitis, otomycosis, necrotizing esophagitis, endocarditis, and peritonitis. Penicilliosis is encountered primarily in immunosuppressed hosts, but corneal infections may be post-traumatically induced. In addition to their infectious potential, *Penicillium* spp., particularly *Penicillium verrucosum*, produces a mycotoxin which is nephrotoxic and carcinogenic. Toxin production usually occurs in long-term storage of cereal grains in cold climates.

2. Additional diseases commonly caused by saprophytic fungi:^(1,2,4,7)

- a. Candidiasis and Thrush
- b. Mucormycosis
- c. Opportunistic pneumonia

Candidiasis: *Candida* may be found in soil, on inanimate objects, in food and in hospital settings. Many *Candida* spp. tend to be commensal flora and can be recovered from numerous sources in and on sick and healthy patients. However, *Candida* spp. may become opportunistic and can produce a wide variety of infections: distinguishing between normal colonization and infection may be difficult. The isolation of *Candida* from “dirty” specimens such as wounds, skin, urine, sputum, or stool is not necessarily diagnostic or indicative of disease; *Candida* isolated from sterile sites such as CSF should be considered diagnostic of infection.

Thrush: Thrush is an overgrowth of *Candida* or yeast, generally found in the oral cavity of human infants, but can also cause foot rot (cattle, sheep, goats) or thrush (horses) in livestock. *Candida* thrives in moist, warm environments and, when overgrown, can be visible as white patches, particularly on the tongue, inside of the cheeks, lips and gums of the oral cavity, or produces a foul smelling black discharge in the affected foot of livestock. There may be pain when applying pressure to the area and the hind feet are more often affected than the front; occasionally, infection may result in a general swelling of the distal (lower) limb. In humans, it can develop in patients who have recently undergone antibiotic therapy, but in livestock it is usually indicative of moist, damp, dirty ground or stable conditions.

Mucormycosis: Mucormycosis is a rare and often fatal disease caused by one of the following fungi: *Mucor*, *Rhizopus*, *Absidia*, or *Rhizomucor*. The disease is also called zygomycosis or phycomycosis and exists as an opportunistic infection that develops in patients with weakened or compromised immune systems. The disease has a poor prognosis with a mortality rate of 30-50% or more, depending upon the condition of the patient.

Opportunistic Fungal Pneumonia: Opportunistic fungal infections commonly cause serious morbidity and mortality in immunocompromised patients. The most significant pathogens include *Cryptococcus neoformans*, *Candida* and *Aspergillus* species, as well as fungi that cause mucormycosis. Clinical and radiological features tend to be highly variable and often nonspecific. Because many of these organisms can colonize the upper airway, sputum cultures are generally considered diagnostically unreliable; a definitive diagnosis requires positive culture and confirmation through microscopic examination.

Definitions and Nomenclature:

Biseriate – phialide supported by a metula (e.g. *Aspergillus terreus*).

Clavate – club-shaped.

Columnar – constructed with or having columns.

Conidium (pl. Conidia, Conidiospores) – specialized portion of a hyphal element that can fragment off as a single cell (spore) and reproduce asexually into a new thallus.

Conidiophore – specialized hypha bearing conidia during asexual reproduction; morphology is distinctive to a specific species.

Dematiaceous – darkly pigmented.

Hypha (pl. Hyphae) – basic tubular filamentous unit of a fungus; a collection of hyphae compose the mycelium.

Muriform – resembling blocks in a wall set in a regular arrangement.

Phialide (pl. Phialides) – specialized cell yielding successive conidia from a fixed location within the thallus.

Radiate – to send out rays or waves.

Septate (pl. Septations) – divided by partitions into discrete cells at regular intervals.





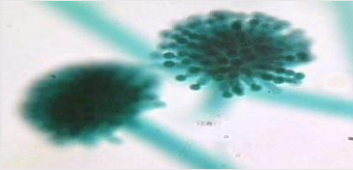
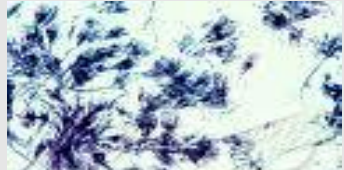

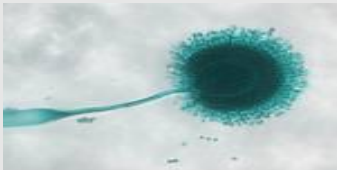

Uniseriate – phialide forming directly on vesicle (e.g. *Aspergillus fumigatus*).

Usual Time – number of days until the appearance of spores and pigment on RSM™.

Vesicle – a swollen cell, often found at the apices of conidiophores.

Table I: Saprophytes Commonly Seen in Human and Veterinary Practice

See definitions and nomenclature above and refer to references.^(3,5,8,9)

	<i>Alternaria</i> spp. (saprophyte)	<i>Aspergillus</i> spp. (saprophyte)	<i>Penicillium</i> spp. (saprophyte)
Species and Incidence	Human: rare (immunocompromised); primary plant pathogen	Human: opportunistic; allergenic; toxigenic; carcinogenic Birds: respiratory (thermophillic) Cattle and Sheep: abortion Poultry: toxicoses	Human: rare (immunocompromised); corneal infections; toxigenic, carcinogenic
Colony Appearance (Top View)	 Dematiaceous; grayish white, turning greenish black or olive brown with light border. Flat, downy to woolly with short grayish aerial hyphae.	 Dematiaceous; downy to powdery; color varies by species (*see table II below)	 Flat, filamentous, velvety, woolly or cottony. White becoming blue-green, gray-green, olive-gray, yellow or pink with age.
Reverse Colony Color (Undersurface view)	Brown to black	Uncolored to pale yellow. Purple to olive (<i>A. nidulans</i>) Orange to purple (<i>A. versicolor</i>)	Pale to yellow
Conidiophores	 Brown hyphae and brown conidiophores.	 Resembles a toilet bowl brush. Flask-shaped phialides, radiate or columnar head.	 Resembles a paint brush with conidia emanating from the top.
Conidiospores	 Muriform, septate conidia; usually club-shaped; UV critical to sporulation	 Round conidiospores in chains on phialides. Clear, septate hyphae.	 Conidiospores in finger-like chains on phialides projecting from vesicles
Usual Time (days)	10-14	10-14	10-14

***Table II: Colony Color Variation in *Aspergillus* spp.**

Species	Colony Appearance (Top View)	Colony Appearance (Reverse View)	Conidiophore	Phialides	Vesicle
<i>A. clavatus</i>	Blue-green	White to brownish with age	Smooth, long	Uniseriate	Clavate, large
<i>A. flavus</i>	Yellow-green	Golden to red brown	Rough, colorless	Uniseriate/Biseriate	Radiate, round
<i>A. fumigatus</i>	Blue-green to gray	White to tan	Smooth, short (<300µm), colorless to green	Uniseriate	Columnar, round
<i>A. glaucus</i> group	Green with yellowing areas	Yellow to brown	Smooth, length varies, colorless	Uniseriate	Radiate to columnar, round
<i>A. nidulans</i>	Green, buff to yellow	Purple red to olive	Smooth, short (<250µm), brown	Short, biseriate	Columnar, round
<i>A. brasiliensis</i> (formerly <i>A. niger</i>)	Black	White to yellow	Smooth, long, colorless to brown	Biseriate	Radiate, round
<i>A. terreus</i>	Cinnamon to brown	White to brown	Smooth, short (<250µm), colorless	Biseriate	Compact columnar, round
<i>A. versicolor</i>	White initially, turning to yellow, tan, pale green or pink	White to yellow or purple red	Smooth, long, colorless	Biseriate	Radiate, round

REFERENCES

1. Anonymous. Saprophyte (Saprobe). UM CLS Program: <http://cls.umc.edu/COURSES/CLS433/CLS433Mycology3.doc>.
2. Haley, L.D. and C.S. Callaway. 1978. *Laboratory Methods in Medical Mycology*. U.S. Dept. of Health, Education and Welfare. CDC. Atlanta, CA.
3. Koneman, E.W., et al. 1997. *Color Atlas and Textbook of Diagnostic Microbiology*, 5th ed. J.B. Lippincott Company, Philadelphia, PA.
4. Laemmlen, F. 2001. *Alternaria* Diseases. *ANR Press*. U.C. Davis, Div. of Ag. and Nat. Res. Pub. 8040.
5. Larone, Davise H. 2002. *Medically Important Fungi: A Guide to Identification*, 4th ed. Washington, D.C.: American Society for Microbiology Press.
6. Muller, G.H. and R.W. Kirk. 1966. *Small Animal Dermatology*. W.B. Saunders Co., Philadelphia.
7. Pattron, D.D. 2006. *Aspergillus*, Health Implication and Recommendations for Public Health Food Safety. *Int. Jour. of Food Safety*. 8:19-23.

8. Rinaldi, M.G., V.J. Stevens, and C. Halde. 1973. *A New Sporulation Medium for Primary Isolation and Identification of Dermatophytes*. Abs: Amer. Soc. Micro. Meeting, Miami.
9. Taplin, D., N. Zaias, G. Rebell, and H. Blank. 1969. Isolation and Recognition of Dermatophytes on a New Medium (DTM). *Arch. Derm.*; 99:203-209.
10. Wilson, J.W. and O.A. Plunkett. 1967. *The Fungous Diseases of Man*. Univ. Calif. Press. Berkeley.
11. Zaias, N., and D. Taplin. 1966. Improved Preparation for the Diagnosis of Mycologic Diseases. *Arch. Derm.*; 93:608-609.

011910kdp

HARDY DIAGNOSTICS

1430 West McCoy Lane, Santa Maria, CA 93455, USA

Phone: (805) 346-2766 ext. 5658

Fax: (805) 346-2760

Website: www.HardyDiagnostics.com

Email: TechService@HardyDiagnostics.com

Distribution Centers:

California · Washington · Utah · Arizona · Texas · Ohio

The Hardy Diagnostics' manufacturing facility and quality management system is certified to ISO 13485.

Copyright© 1996 - 2010 by Hardy Diagnostics. All rights reserved.